



New Berlin Animal Hospital
3840 S. Moorland Rd.
New Berlin, WI 53151
Office: 262.782.6910
Web Site: NBAnHosp.com



GLAUCOMA

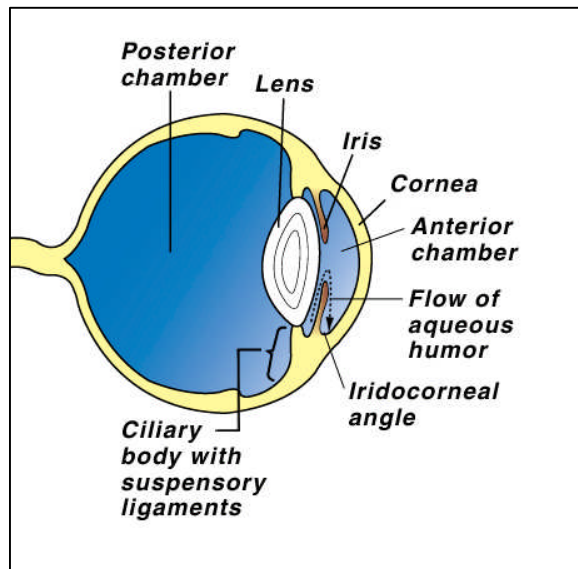
The size and shape of the normal eye is maintained by the amount of fluid within the eyeball. The pressure of the fluid in the eye is known as Intra-ocular Pressure (IOP). Fluid is constantly produced by a structure called the *ciliary body*. In addition to producing this fluid (aqueous humor), the ciliary body contains the *suspensory ligaments* which hold the lens in place. Muscles in the ciliary body pull on the suspensory ligaments that control the shape and focusing ability of the lens.

Aqueous humor contains nutrients and oxygen, which are used by the structures within the eye. The excess fluid is constantly drained from the eye between the cornea and the iris. This area is called the *iridocorneal* or drainage angle.

The pressure remains constant as long as the production and absorption of aqueous is equal.

What is glaucoma?

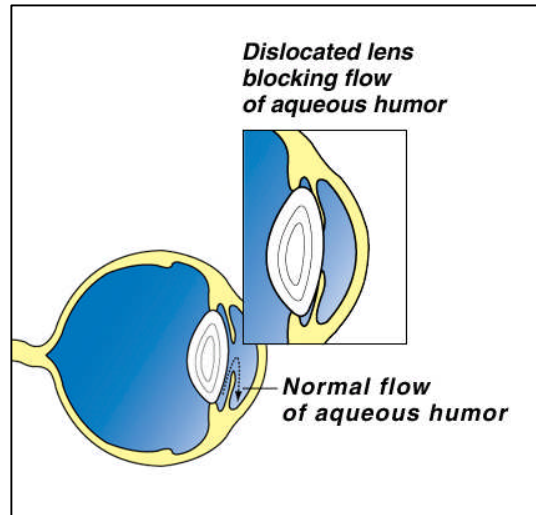
Glaucoma is an increase in IOP. This is measured using an instrument called a *tonometer*. The cause of glaucoma is related to inadequate drainage of aqueous rather than its over production. Glaucoma may be primary or secondary.



Primary glaucoma results in increased intra-ocular pressure in a healthy eye. Some breeds are more prone than others. It occurs due to inherited anatomical abnormalities in the drainage angle. For example, in *narrow angle glaucoma* there is a shallow anterior chamber which causes the iris to block the iridocorneal angle interfering with the filtration. Abnormalities in the drainage angle (goniodysgenesis) can lead to a raised IOP in middle age.

Secondary glaucoma results in increased intra-ocular pressure due to disease or injury to the eye. This is the most common cause of glaucoma in dogs and cats. Causes include:

- Uveitis (inflammation) resulting in debris and scar tissue blocking the drainage angle, and severe intra-ocular infections.
- Tumors which cause physical blockage of the iridocorneal angle.
- Intra-ocular bleeding. The blood clot can prevent drainage of the aqueous humor.
- Damage to the lens. Lens proteins leaking into the eye as a result of a ruptured lens can cause a reaction which results in swelling and blockage of the drainage angle.
- Anterior dislocation of lens. The lens falls forward and physically blocks the drainage angle or pupil such that fluid is trapped behind the dislocated lens.



How is glaucoma diagnosed?

The most common clinical signs noted by owners are:

- Ocular pain, your dog may partially close and rub at the eye. He may turn away as you touch or pet the side of his head.
- A watery discharge from the eye and the dog becomes depressed.
- Physical swelling and bulging of the eyeball become obvious. The white of the eye looks red and engorged.
- The cornea or clear part of the eye may become cloudy (usually bluish in color).
- Blindness. Blindness can occur very quickly unless the increased IOP is reduced.

All these signs can occur very suddenly with acute glaucoma. In chronic glaucoma they develop more slowly. They may have been present for some time before your pet shows any signs of discomfort or clinical signs.

Diagnosis depends upon accurate IOP measurement (tonometry) and internal eye examination using special instruments.

Acute glaucoma is an emergency. Sometimes referral to a veterinary ophthalmologist is necessary.

Treatment

It is important to reduce the IOP as quickly as possible to reduce the risk of irreversible damage and blindness.

It is also important to treat any underlying disease that may be responsible for the glaucoma.

Medical treatment often must be combined with surgery. Analgesics are prescribed to control the pain and discomfort associated with the condition.

Veterinary ophthalmologists use various surgical techniques to reduce intra-ocular pressure. If you have any difficulties with your pet's medications, please call us immediately.