



New Berlin Animal Hospital
3840 S. Moorland Rd.
New Berlin, WI 53151
Office: 262-782-6910
Web site: NBAnHosp.com



CAUDA EQUINA OR LUMBOSACRAL SYNDROME

What is the cauda equina or lumbosacral syndrome?

This is a disease that occurs at the lumbosacral junction in the lower back. The term *lumbo* refers to the lumbar vertebrae. These are the bones in the lower part of the spinal column. The term *sacral* refers to the sacrum, which is the part of the spine that joins the lumbar spine and the pelvis.

This disease is also known as the cauda equina syndrome. This term comes from the Latin for "horse's tail". At this level, the spinal cord is no longer a tubular structure. Instead, it is a collection of large nerves that have the appearance of a horse's tail.

Lumbosacral syndrome is instability at this strategic point in the spine.

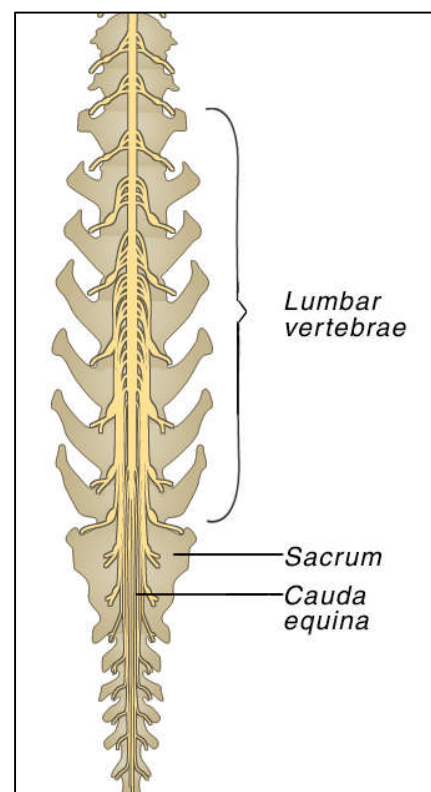
What causes it?

Pressure on the cauda equina or the nerves that exit the spine causes the clinical signs. The pressure may be due to a narrowed spinal canal, an infection in the disc at this joint, trauma, a spinal tumor or instability at this joint.

What are the clinical signs?

When instability exists along the spine, abnormal movement of the spinal cord occurs. This causes inflammation of the spinal cord and muscles in the affected area. Dogs with lumbosacral syndrome are in pain. When pressure is applied to the muscles in the lower back, many dogs will cry or move away. Some dogs may be slow to rise from a lying position because this movement aggravates the inflamed nerves and muscles. Some will literally fall to their knees when the tail is lifted sharply. Occasionally, dogs develop weakness or lameness in the rear legs with muscle atrophy. Others have fecal or urinary incontinence, and some will mutilate their feet or tail with incessant chewing.

As the problem progresses, the disc that is located between the last lumbar vertebrae and the sacrum may rupture. If this happens, the dog will be uncoordinated when it walks, or it may be paralyzed in the rear legs.



How is it diagnosed?

Radiographs (x-rays) will generally reveal arthritic changes at the lumbosacral junction. However, this is common in many dogs and may not cause any clinical signs. If the disc ruptures, there may be evidence of a narrowed disc space or disc material against the spinal cord. However, these signs offer only indirect evidence.

If the clinical signs and radiographs are suggestive of cauda equina syndrome, a special radiographic study, called a myelogram, is performed. This is the injection of contrast material around the spinal cord so that pressure on the spinal cord can be detected on subsequent radiographs.

What is the treatment?

If your dog is overweight, weight reduction will be an important part of the treatment. Any disorder of the back is aggravated by excessive body weight.



Strict rest is also an important part of treatment for any back problem. Cage rest is preferable but confinement in a small fenced run or small room is acceptable.

Anti-inflammatory drugs and pain relievers will often give temporary relief.

Although infection in the disc is not a common cause, it should be treated with appropriate antibiotics if it is present. An infection of this nature usually requires 4-8 weeks of therapy.

If the disc ruptures, many dogs will become uncoordinated when they walk, or become paralyzed in the rear legs. If this occurs, surgery is indicated. The surgical procedure, called a dorsal laminectomy, is to relieve the pressure of a bulging or ruptured disc from the spinal cord. It also permits identification of a spinal tumor or narrowing of the spinal canal due to traumatic injury. Once the pressure is relieved, return of function of the rear legs is expected.

However, permanent damage to the spinal cord will not be reversed, and the surgery does not relieve inflammation around the spinal nerves or the muscles. Continued pain relievers or anti-inflammatory drugs may be needed until this aspect of the problem finally resolves.